

## Original Research Article

# Sutureless, bloodless, safe new circumcision technique

Wael Barakaat Ahmed Mohamed\*, Ahmed Eisa Ahmed

Department of General Surgery, Sohag University Hospitals, Sohag, Egypt

**Received:** 19 May 2017

**Accepted:** 17 June 2017

**\*Correspondence:**

Dr. Wael Barakaat Ahmed Mohamed,

E-mail: [waelbarakaat1979@gmail.com](mailto:waelbarakaat1979@gmail.com)

**Copyright:** © the author(s), publisher and licensee Medip Academy. This is an open-access article distributed under the terms of the Creative Commons Attribution Non-Commercial License, which permits unrestricted non-commercial use, distribution, and reproduction in any medium, provided the original work is properly cited.

### ABSTRACT

**Background:** Several techniques of circumcision are available such as conventional surgical technique, the device (Gomco, Plastibell), mono and bipolar diathermy and sutureless methods such as fibrin glue. Our knowledge, the first report of using harmonic scalpel in circumcision was published by Peng et al, in the Asian journal of andrology but the study was done on dogs, this one of the little studies describe the use of the harmonic scalpel in male circumcision in humans. Aim was to describe the technique of the harmonic scalpel circumcision and report its outcomes in the term of safety and efficacy.

**Methods:** This was a prospective observational study performed in the general surgery department at Sohag university hospital, Sohag, Egypt from 1st January 2015 to 31 December 2016.

**Results:** 90 male patients were included in this study. Their age ranged between 3 and 18 years. The most common indication was religious circumcision 50%. No intraoperative blood loss or a postoperative bleeding. One case of wound infection and three cases of a postoperative edema respond to conservative treatment. No injury to the surrounding structure.

**Conclusions:** The result of this study determines that the harmonic scalpel circumcision not associated with intraoperative blood loss or postoperative bleeding and a good postoperative cosmetic result, with a minimal complication. So, it is an appropriate alternative to the traditional scalp and suture technique.

**Keywords:** Circumcision, Harmonic, Male, Penis, Phimosis, Sutureless

### INTRODUCTION

One of the oldest procedure performed in Egypt is the male circumcision, the pharos had circumcised and evidence was present in the Egyptian mummies (2300BC), circumcision is the most common procedure performed worldwide.<sup>1,2</sup> It is suggested that more than one-third of world male population had circumcised.<sup>3</sup>

The practice of circumcision was supported by evidence-based medicine in the USA and Australia.<sup>4,5</sup>

Many studies suggest that circumcision has many benefits such protection against prostatic cancer, urinary

tract infection and sexually transmitted diseases such as HIV.<sup>5-7</sup> It is also had many advantages to the female partner such as protection against cervical cancer and sexually transmitted diseases.<sup>5,6</sup> Circumcision has a wide variety of indications worldwide. One of the most common indications was religious or culture (non-therapeutic indication) that performed by the Jewish and Muslims while in the western countries it is mostly performed for medical causes.<sup>7</sup>

Several Techniques of circumcision are available such as conventional surgical technique, the device (Gomco, Plastibell), mono and bipolar diathermy and Sutureless methods such as fibrin glue.<sup>8</sup>

Our knowledge, the first report of using the harmonic scalpel in circumcision was published by Peng et al, in the Asian journal of andrology but the study was done on dogs.<sup>9</sup> Up to the knowledge, this one of the little studies describe the use of the harmonic scalpel in male circumcision in human. Aim was to describe the technique of the harmonic scalpel circumcision and report its outcomes in the term of safety and efficacy.

## METHODS

This was a prospective observational study performed in the general surgery department at Sohag university hospital, Sohag, Egypt from 1<sup>st</sup> January 2015 to 31<sup>st</sup> December 2016.

A written consent was obtained from all the child-parent before the procedure. Ethical committee approval was obtained from the faculty before the beginning of the study. Complete blood picture and coagulation profile were routinely done in all patients.

### Inclusion cercaria

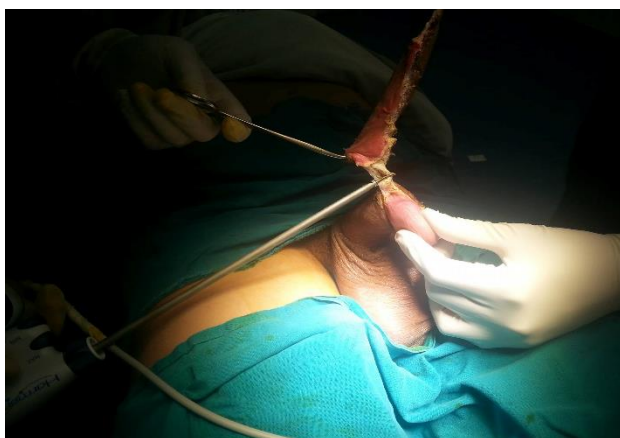
Age between 3-18 years old.

### Exclusion criteria

- Age less than 3 or more than 18 years
- Bleeding tendency
- Congenital anomalies such as hypospadias and epispadias

### Surgical techniques

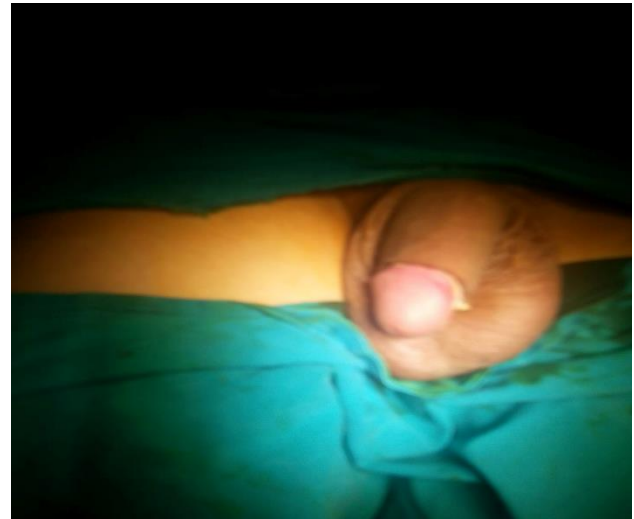
All the procedures were performed in the operating room under general anesthesia, after preparation of the penis and surrounding area by chlorohexidine 2% solution, covering the area with sterile drape was done. The device was adjusted to the minimum level of 3.



**Figure 1: Dissection using the harmonic scalpel.**

The prepuce was retracted the smegma was removed, cleaning of the sulcus from any debris was done. Any

adhesion between the ventral aspect of the glans and prepuce was divided using harmonic scalpel, two hemostats applied to the prepupal skin at 3 and 9 o'clock position, then incision of the ventral aspect of the prepuce was done using harmonic scalpel at 12 o'clock position the active blade applied to the skin up to the coronal sulcus then prepupal skin removed circumferentially to the ventral aspect up to 6oclock position care should be taken to avoid damage to the glans or urethra, it is a sutureless technique.



**Figure 2: The final view.**

### Postoperative care

All patients were discharged from the hospital after recovery from anesthesia and toleration of oral feeding. the patient discharged on analgesic and combination of steroid and antibiotic cream. Follow up in outpatient clinic was done after one and two weeks.

## RESULTS

**Table 1: Present the indication for circumcision.**

Indication	Number	Percentage
Religious	45/90	50%
Phimosis	20/90	22.22%
Recurrent balanitis	25/90	27.78%

**Table 2: Report and postoperative outcome the operative.**

Operative and postoperative outcome	
Intraoperative blood loss	0 ml
Operative time	Range between 3-10 minutes
Postoperative bleeding	0/90
Edema	3/90
Wound infection	1/90
Wound dehiscence	0/90
Urethral injury	0/90

Between January 2015 and December 2016, 90 male patients were included in current study. Their age ranged between 3 and 18 years. The indication of circumcision was presented in Table 1, the most common indication was religious circumcision.

## DISCUSSION

Male circumcision is one of the most popular operations worldwide. The rate of circumcision varies from one area of the world to another due to the difference in the religious and cultural background in Muslim countries more than 99% of males are circumcised.<sup>10</sup> There are many techniques used to do circumcision such as the traditional excision and suture technique using absorbable suture to approximate the wound; however, development of granuloma and persistent mark on the suture line give unsatisfactory cosmetic results.<sup>11</sup> In the last century, development of sutureless techniques such as tissue glue, bipolar diathermy and monopolar diathermy with satisfactory results were reported in many studies.<sup>12</sup> To the knowledge, little information about the use of harmonic scalpel in circumcision as previously stated, we found a report of the use of the harmonic scalpel in circumcision in dogs by Peng M et al.

The most surprising result of this study, that there were no intraoperative blood loss or postoperative bleeding. The incidence of bleeding due to circumcision varies from 0.5% to 5%.<sup>13</sup> Study can explain result as the harmonic scalpel can coagulate vessels up to 0.5 mm, also many studies do not recommend the use of sutureless circumcision in boys more than 12 years old as the erection may increase the risk of wound dehiscence and bleeding; however, in this study no wound dehiscence or bleeding were reported although sutureless circumcision was done to boys up to 18 years old. This is due to the sealing effect of the harmonic scalpel.<sup>14</sup>

The technique was sutureless so no foreign body granuloma or marks of suture line and this gives a good cosmetic result. 3 cases of postoperative edema were recorded but no interference with wound approximation was detected. All cases respond to conservative management.

Several studies were published about sutureless circumcision using tissue glue. All of them reported superior cosmetic result due to an absence of the mark at the suture line.<sup>15,16</sup>

In this study, the range of operative time between 3 and 10 minutes which is shorter than the traditional circumcision and then other techniques of sutureless circumcision. In 2005 Ozkan KU and Gonen M reported an average operative time 19.8 minutes with the use of tissue glue and 16 minutes with suturing and explain that the application of glue takes a longer time.<sup>16</sup> Fraser ID and Goede AC, reported an operative time of 11.4 minutes for sutureless circumcision versus 13.8 minutes

for the conventional technique using suture.<sup>17</sup> In present study, no application of tissue adhesive or suturing was done and this can explain the shorter operative time in this study.

One of the limitations of the use of the harmonic scalpel in male circumcision is that it is an expensive technique requiring harmonic generator in addition to the harmonic scalpel. However, in many hospitals these devices are available and already used in laparoscopic surgery, it can be reused after sterilization and that may decrease the cost, also the operative time is about six fold lesser than conventional technique and this can save time and effort and may reduce the cost.<sup>10</sup>

The main limitation of this study is that a single arm descriptive non-randomized study on a small number of patients so, in the future, we need to conduct a large multi-center randomized control study.

## CONCLUSION

The result of this study determines that harmonic scalpel circumcision is not associated with intraoperative blood loss or postoperative bleeding and a good postoperative cosmetic result, with a minimal complication. So, it is an appropriate alternative to the traditional scalpel and suture technique.

*Funding: No funding sources*

*Conflict of interest: None declared*

*Ethical approval: The study was approved by the institutional ethics committee*

## REFERENCES

1. Mokul N, Chavan N. Modified safe technique for circumcision. Indian J Plast Surg. 2008;41:47-50.
2. Rizvi S, Nagvi S, Hussain M, Hasan A. Religious circumcision: a Muslim view. Br J Urol Int. 1999;83:13-6.
3. Williams N, Kapila L. Complications of circumcisions. Br J Surg. 1993;80:1231-4.
4. American academy of Pediatrics. Male circumcision. Pediatrics. 2012;130:756-85.
5. Morris BJ, Mindel A, Tobian AA, Hankins CA, Gray RH, Bailey RC, et al. Should male circumcision be advocated for genital cancer prevention? Asian Pac J Cancer Prev. 2012;13(9):4839-42.
6. Morris BJ, Gray RH, Castellsague X, Bosch FX, Halperin DT, Waskett JH, et al. The strong protective effect of circumcision against cancer of the penis. Adv Urol. 2011;2011:812368.
7. Gerharz EW, Haarmann C. The first cut is the deepest? medicolegal aspects of male circumcision. BJU Int. 2000;86:332-8.
8. Tucker SC, Cerqueiro J, Sterne GD, Bracka A. Circumcision: a refined technique and 5-years review. Ann R Coll Surg Engl. 2001;83:121-5.

9. Peng M, Meng Z, Yang ZH, Wang XH. The ultrasonic harmonic scalpel for circumcision: experimental evaluation using dogs. *Asian J Androl*. 2013;15:93-6.
10. Schosen EJ. The status of circumcision in newborn. *New E J Med*.1990;322:1308-1322.
11. Arunachalam P, King PA, Orford J. A prospective comparison of tissue glue versus sutures for circumcision. *Pediatr Surg Int*. 2003;19:18-9.
12. Subramaniam R, Jacobsen AS. Sutureless circumcision: a prospective randomized controlled study. *Pediatr Surg Int*. 2004;20:783-5.
13. Kaplan GW. Complications of circumcision. *Urol Clin North Am*. 1983;10:543-6.
14. Lane V, Vajda P, Subramaniam R. Pediatric sutureless circumcision: a systematic literature review. *Pediatr Surg Int*. 2010;26:141.
15. Kelly BD, Lundon DJ, Timlin ME, Sheikh M, Nusrat NB, D'Arcy FT, et al. Paediatric sutureless circumcision: an alternative to the standard technique. *Pediatr Surg Int*. 2012;28:305-8.
16. Ozkan KU, Gonen M. Wound approximation with tissue glue in circumcision. *Int J Urol*. 2005;12:374-7.
17. Fraser ID, Goede AC. Sutureless circumcision. *BJU Int*. 2002;90:467-8.

**Cite this article as:** Mohamed WBA, Ahmed AE. Sutureless, bloodless, safe new circumcision technique. *Int Surg J* 2017;4:2530-3.